

Does Malrotation of the Tibial and Femoral Components Compromise Function in Kinematically Aligned Total Knee Arthroplasty?

Alexander J. Nedopil, MD^{a,*}, Stephen M. Howell, MD^b,
Maury L. Hull, PhD^c

KEYWORDS

- Knee arthroplasty • Internal and external rotation • Malrotation of components
- Kinematic alignment • Oxford knee and WOMAC scores • Function

KEY POINTS

- Association between femoral component rotation and function.
- Association between tibial component rotation and function.
- WOMAC and Oxford Knee Score determined function.
- High function after kinematic aligned total knee arthroplasty.
- Weak association between component rotation bounded by the ranges reported in the present study and function.

INTRODUCTION

Internal and external (I-E) malrotation of the femoral and tibial components is associated with poor function after total knee arthroplasty (TKA).^{1,2} In mechanically aligned TKA, there are several reference lines in use to minimize I-E malrotation of the femoral and tibial components. Three reference lines used to set I-E rotation of the femoral component are

1. The line parallel to the anterior-posterior (A-P) axis of the trochlear groove,
2. The line parallel to the transepicondylar axis, or

3. The line 3° externally rotated to the posterior condylar line of the femur.³

Four reference lines used to set I-E rotation of the tibial component are

1. The line between the most medial and most lateral points of the plateau,
2. The line between the medial one-third of the tubercle and the center of the PCL attachment,
3. The line between the medial border of the tubercle and the PCL, and
4. The line between the projection of the anterior crest and the PCL.⁴

Disclosures: The authors have not received grant support or research funding and do not have any proprietary interests in the materials described in the article.

^a Department of Orthopaedics, University of California, Davis, 4860 Y Street, Suite 3800, Sacramento, CA 95817, USA; ^b Department of Biomedical Engineering, University of California, Davis, Sacramento, CA 95817, USA;

^c Department of Mechanical Engineering, University of California, Davis, Sacramento, CA 95817, USA

* Corresponding author.

E-mail address: nedopil@ucdavis.edu

Orthop Clin N Am 47 (2016) 41–50

<http://dx.doi.org/10.1016/j.ocl.2015.08.006>

0030-5898/16/\$ – see front matter © 2016 Elsevier Inc. All rights reserved.

However, the range of I-E malrotation of the femoral component (-13° internal to 16° external; $SD \pm 7^\circ$) and of the tibial component (-44° internal to 46° external; $SD \pm 28^\circ$) reported for these reference lines is high, which indicates the placement of these lines is not reproducible.^{3,4}

Kinematic alignment is a new method that has gained interest because 2 studies showed that patients with a kinematically aligned TKA reported better pain relief, better function, better flexion, and a more normal-feeling knee than patients with a mechanically aligned TKA.^{5,6} The goal of kinematic alignment is to correct the arthritic deformity of the limb to the constitutional alignment of the patient with the intent of positioning the femoral and tibial components so that the natural tibial-femoral articular surface, alignment, and laxities of the knee are restored. This is accomplished in part by setting the A-P axes of the femoral and tibial components parallel to the flexion-extension (F-E) plane of the extended knee (Fig. 1). The F-E plane of the extended knee is aligned perpendicular to the F-E axis of the tibia that connects the 2 centers of the circular portion of the posterior femoral condyles from about 20° to 120° and parallel to the F-E axis of the patella and the natural distal and posterior femoral joint lines.⁷⁻¹³

Surgically, the A-P axis of the femoral component is set parallel to the F-E plane of the extended knee by placing a 0° rotation posterior referencing guide in contact with the posterior femoral condyles at 90° and removing posterior femoral resections within ± 0.5 mm of the thickness of the condyles of the femoral component after compensating for cartilage wear and kerf.¹⁴ Surgically, the A-P axis of the tibial component is set parallel to the F-E plane of the extended knee by aligning the A-P axis of the tibial component parallel to the major axis of the elliptical-shaped boundary of the lateral tibial condyle (Fig. 2).¹⁵ However, there are no data reporting

the range of I-E malrotation of the femoral and tibial components when these methods of rotational alignment are used to perform a kinematically aligned TKA.

The objectives of the present study were to determine the range of I-E malrotation for both components in a case series of patients treated with a kinematically aligned TKA and then determine whether the degree of I-E malrotation of the femoral and tibial components compromised function as measured by the Oxford Knee Score (OKS) and the Western Ontario and McMaster Universities Osteoarthritis Index (WOMAC) score.

METHODS

An institutional review board approved the analyses of 101 consecutive patients (101 knees) treated with a primary kinematically aligned TKA from June to September, 2012, by an inventor surgeon (S.M.H.) who were prospectively followed for 6 months. When feasible, patients were scheduled for a preoperative MRI scan to evaluate cartilage wear and plan the thickness of the posterior resections from the femur. Thirty patients were excluded because they were unable to have our protocol preoperative MRI because of a pacemaker, hardware about the knee, insurance refused to authorize, or an MRI had been performed with a different protocol. The indications for performing kinematically aligned TKA were

1. Disabling knee pain and functional loss unresolved with standard of care, nonoperative, treatment modalities;
2. Radiographic evidence of advanced arthritis indicated by a Kellgren-Lawrence grade of 3 or 4; and
3. Any severity of varus and valgus deformity and flexion contracture.

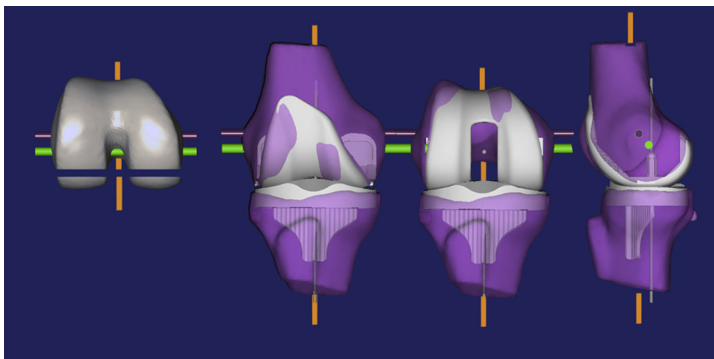


Fig. 1. A right femur with posterior femoral resections equal in thickness to the condyle of the femoral component and 3 views of a kinematically aligned TKA. The green line in the femur is the F-E axis of the tibia. The magenta line in the femur is the F-E axis of the patella. The orange line is parallel to the F-E plane of the extended knee, which is perpendicular to the F-E axis of the tibia, the F-E axis of the patella, and a line tangent to the distal and posterior femoral condyles.

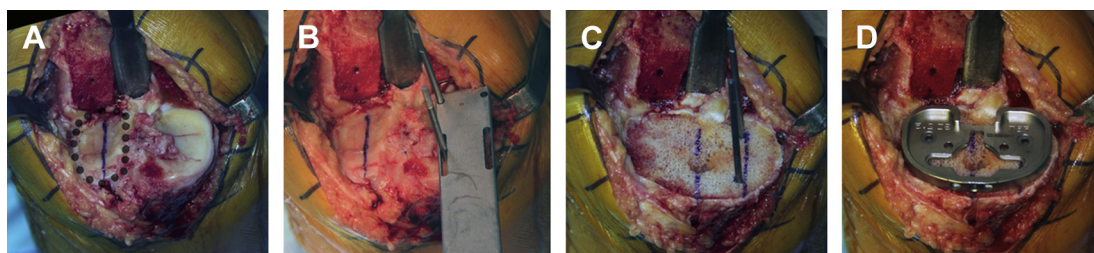


Fig. 2. Intraoperative proximal view of a right tibia and the surgical steps for kinematically aligning the I-E rotation of the A-P axis of the tibial component parallel to the F-E plane of the extended knee. The black dots outline the boundary of the articular surface of the lateral tibial condyle, and the blue line is the approximate long axis connecting the most anterior and distal points on the boundary (A). Two pins are drilled parallel to the blue line through the articular surface of the medial tibial condyle with a guide (B). On the cut surface of the tibia, 2 lines are drawn parallel to the 2 drill holes (C). The rotation of the A-P axis of the tibial component is set parallel to these 2 lines (D).

Seventy-one patients (71 knees) with an average (SD) age of 68 ± 8.6 years, of whom 30 were men, met our inclusion criterion and were included in the analysis (Table 1). The number (percent) of patients with a 5° to 10° varus deformity was 22 (31%), 11° to 15° varus deformity was 18 (26%), greater than 16° varus deformity was 9 (12%), 10° to 15° valgus deformity was 12 (17%), 16° to 20° valgus deformity was 7 (10%), and greater than 20° valgus deformity was 3 (4%). Patient-reported OKS and WOMAC score at 6 months determined function. Function was measured at 6 months because the New Zealand Joint Registry 2014 showed that 6-month OKS predict the

revision rate at 2 years and the function at 5 years.¹⁶

The preoperative MRI scan was obtained in an oblique sagittal plane oriented parallel to the F-E plane of the extended knee with a 1.5-T scanner and a dedicated knee coil (General Electric Medical Systems, Milwaukee, WI, USA). The F-E plane of the extended knee is perpendicular to F-E axes of the tibia and patella, and the distal and posterior joint lines of the femur.¹⁷ The following parameters were used: fast-relaxation fast-spin-echo proton density, echo time, 30 to 35 milliseconds, repetition time, 2800 to 3400 milliseconds; bandwidth, 31.25 Hz; a minimum of 2 excitations with a

Table 1
Preoperative demographics and clinical characteristics for the patients treated in the present study

Preoperative Demographics and Clinical Characteristics	Number of Patients or Knees	Mean (SD) or Number (%)	Range
Demographics			
Age (years)	<i>N</i> = 71	68 (8.6)	45–86
Sex (male)	<i>N</i> = 30	42%	—
Body mass index (kg/m^2)	<i>N</i> = 71	31 (5.1)	19–42
Anesthesia Society of Anesthesiologists Score (ASA) (1 is best, 4 is worst)	<i>N</i> = 71	1 (0%), 2 (69%), 3 (23%), 4 (8%)	—
Preoperative motion and deformity			
Extension (degrees)	<i>N</i> = 69	11 (8.2)	0–40
Flexion (degrees)	<i>N</i> = 69	112 (9.5)	80–150
Varus (+)/valgus (–) deformity (degrees)	<i>N</i> = 71	1 (13.5)	–30–20
Preoperative function and mental scores			
Oxford Score (48 is best, 0 is worst)	<i>N</i> = 69	23 (7.7)	3–36
Knee Society Score (100 is best, 0 is worst)	<i>N</i> = 69	34 (11.7)	8–74
Knee Function Score (100 is best, 0 is worst)	<i>N</i> = 69	52 (17.8)	0–100
SF-12 Physical Score (50 average)	<i>N</i> = 68	29 (6.1)	14–47
SF-12 Mental Score (50 average)	<i>N</i> = 68	53 (10.4)	24–68

16-cm field of view centered at the joint line of the knee, 256×224 matrix; slice thickness, 2 mm; and no spacing/gap.

Each kinematically aligned TKA was performed with US Food and Drug Administration-approved generic instruments and cruciate-retaining, fixed-bearing components (Triathlon; Stryker, Inc, Mahwah, NJ, USA), and with a technique previously described.^{14,15,18} The following steps are detailed because they set the varus-valgus (V-V), proximal-distal (P-D), I-E, A-P, and F-E locations of the femoral and tibial components when performing kinematically aligned TKA.

For the placement of the femoral component, the V-V and P-D locations of the distal femoral resection were set using an offset distal femoral referencing guide that contacted the distal medial and lateral femoral condyles. The offset was selected to compensate for 2 mm of cartilage wear on the worn condyle(s), which corrected the V-V deformity caused by wear. The P-D level of the distal femoral resection was set so that the thickness of the resections of the distal medial and lateral femoral condyles equaled the condylar thickness of the femoral component after compensating for cartilage wear and kerf.^{14,19} The A-P and I-E locations of the posterior femoral resection were set parallel to the F-E plane of the extended knee by placing a 0° rotation posterior referencing guide in contact with the posterior femoral condyles at 90° and removing posterior femoral resections within ± 0.5 mm of the thickness of the condyles of the femoral component after compensating for cartilage wear and kerf.¹⁴ The thickness of each posterior resection was measured with a caliper. Over or under resection of 1 or 2 mm was corrected by adjustment of the position of the chamfer block and then performing the anterior and chamfer cuts to hold the new position of the femoral component. Compensation for cartilage and bone wear at 90° on the posterior femoral condyles was rarely needed when treating grade 3 and 4 Kellgren-Lawrence osteoarthritic knees.¹⁹

For the placement of the tibial component, the V-V, P-D, and F-E locations of the tibial resection were set using an extramedullary tibial guide and an angel wing inserted in the saw slot alongside the medial border of the tibia. The V-V position of the tibial component was set by medial translation of the slider at the ankle section of the guide until the saw slot was parallel to the tibial articular surface after a visual compensation for cartilage and bone wear. When the extension gap was asymmetric or trapezoidal, the V-V angle of the tibial resection was fine-tuned in increments of 1° to 2° until the gap was symmetric and V-V laxity was eliminated. Elimination of the V-V laxity with

the knee in extension minimized any confounding effect that the V-V angles of the resection might have had on I-E rotation of the components. The F-E position of the tibial component was set by adjustment of the slope of the tibial guide until the angel wing was parallel to the slope of the medial joint line. The P-D position of the tibial component was set by adjustment of the level of the saw slot to remove enough tibia to accommodate a 10-mm-thick tibial component.¹⁴ The I-E rotation of the A-P axis of the tibial component was set parallel to the F-E plane of the extended knee by alignment of the A-P axis parallel to the long axis of the boundary of the lateral tibial condyle (see Fig. 2).¹⁵ The long axis was defined as the line connecting the most anterior and posterior points on the boundary. In all cases, the patella was resurfaced and all components were cemented. A 1.25-mm thick axial computed tomography (CT) scan of the hip, knee, and ankle was performed on each patient before discharge using a previously described technique.^{15,20}

The following technique computed the I-E malrotation of the A-P axis of the femoral and tibial components from the F-E plane of the extended knee using free image-analysis software (OsiriX Imaging Software, <http://www.osirix-viewer.com>) by 1 author (A.J.N.) blinded to the function scores (Fig. 3). The CT scan was opened with the 3D MPR tool. The axial view was optimized by orienting the image plane tangential to the distal surface of the tibial baseplate, which required adjustment of the P-D and V-V plane in the coronal window and adjustment of the F-E plane in the sagittal window. The DICOM export tool was used to export the optimized axial plane of the knee at a 1.25-mm slice thickness. The axial images of the preoperative MRI and postoperative CT scans were opened side by side. The P-D level of each scan was adjusted until the projection of the femoral epicondyles on the MRI and CT scans matched. The matched images were linked with the sync tool. The femoral reference line connecting the medial and lateral epicondyles was drawn on the MRI and CT scan. The P-D level was adjusted until the posterior condylar axis of the tibia was viewed on the MRI and CT scans. The tibial reference line was drawn tangent to the posterior tibia on the MRI and CT scans. The P-D level was adjusted until the largest dimension of the intercondylar notch was viewed on the MRI scan. A line parallel to the F-E axis of the extended knee was drawn perpendicular to the posterior condylar axis of the femur. The P-D level was adjusted until the lugs on the femoral component were viewed on the CT scan. The A-P axis of the femoral component was drawn perpendicular to a line connecting the lugs. The P-D

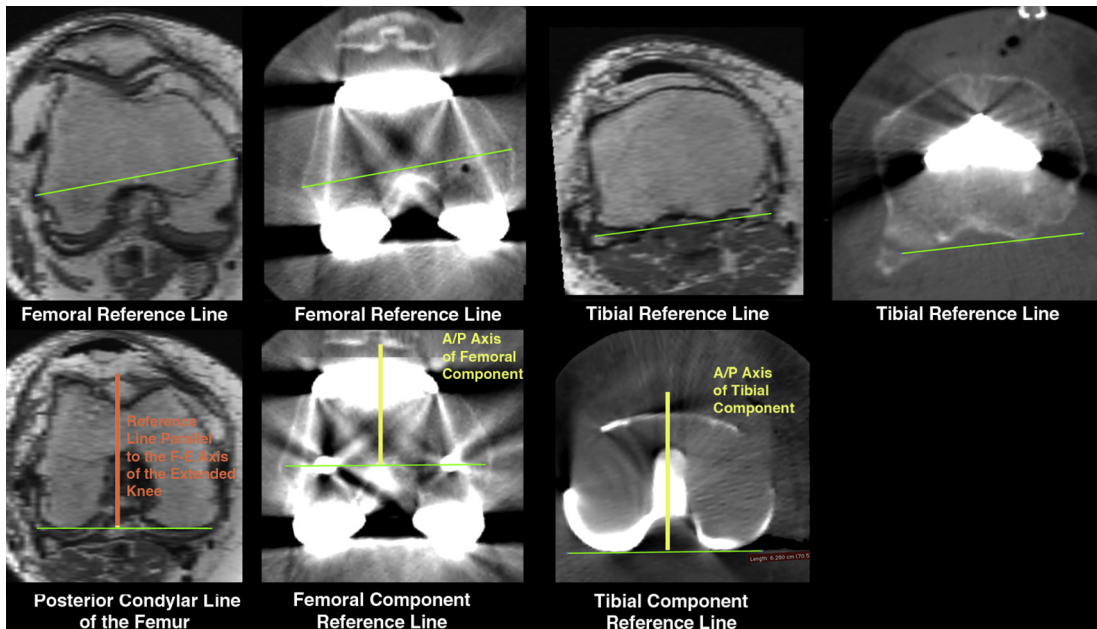


Fig. 3. Matched axial views of the femur and tibia on the preoperative MRI and postoperative CT scans. The femoral reference line connects the femoral epicondyles. The tibial reference line connects the posterior tibial condyles. The reference line perpendicular to the posterior condylar line of the femur on the MRI is parallel to the F-E plane of the extended knee. The A-P axis of the femoral component is perpendicular to the femoral component reference line. The A-P axis of the tibial component is perpendicular to the tibial component reference line.

level was adjusted until the posterior border of the tibial component or liner was viewed on the CT scan. The A-P axis of the tibial component was drawn perpendicular to a line tangent to the posterior condylar axis of the tibial component or liner. On the MRI scan, the angle between the femoral and the tibial reference lines and the line parallel to the F-E plane of the extended knee was computed. On the CT scan, the angle between the femoral reference line and the A-P axis of the femoral component was computed. On the CT scan, the angle between the tibial reference line and the A-P axis of the tibial component was computed. These angles enabled the determination of the I-E malrotation of the A-P axis of the femoral and tibial components on the CT scan from the line parallel to the F-E axis of the extended knee on the MRI scan (+ indicated external and – indicated internal malrotation of the components from the F-E plane of the extended knee).

Statistical Analysis

The reproducibility of the measurement of the I-E malrotation of the femoral and tibial components from the F-E plane of the extended knee was determined by computing the intraclass correlation coefficient (ICC) with use of measurements

made on 10 randomly selected knees by 2 observers. The arithmetic mean, SD, and 95% confidence interval (CI) of the mean and SD were computed for each measured quantity when appropriate (JMP, 10.02, <http://www.jmp.com>). A simple regression determined the strength of the association between the I-E malrotation of the femoral and tibial component from the F-E plane of the extended knee and patient-reported function (OKS and WOMAC score). Significance was $P < .05$.

RESULTS

The ICC of 0.91 for the measurement of I-E malrotation of the femoral component and the ICC of 0.97 for the measurement of I-E malrotation of the tibial component indicated high (first class) measurement reproducibility.

The best achievable OKS is 48 (range 0–48), and the mean patient-reported OKS was 42 ± 4.5 (95% CI, 41.2 to 43.4). The best achievable WOMAC score is 100 (range 0–100), and the mean WOMAC score was 89 ± 9.7 (95% CI, 86.7–91.3).

The I-E malrotation of the A-P axis of the femoral component ranged from -3° internal to 2° external (mean $0.3^\circ \pm 1.1^\circ$; 95% CI of the mean, 0° – 0.6° ; 95% CI of the SD, 0.9° – 1.3°) from the F-E plane

of the extended knee. There was a weak association between the I-E malrotation of the femoral component from the F-E plane of the extended knee and the OKS ($r^2 = 0.0284$) and the WOMAC score ($r^2 = 0.011$) (Fig. 4).

The I-E malrotation of the A-P axis of the tibial component ranged from -11° internal to 12° external (mean $-1.0^\circ \pm 5.4^\circ$; 95% CI of the mean, -2.3° to 0.30° ; 95% CI of the SD, 4.7° – 6.5°) from the F-E plane of the extended knee. There was a weak association between the I-E malrotation of the tibial component from the F-E plane of the extended knee and the OKS ($r^2 = 0.0265$) and the WOMAC score ($r^2 = 0.0256$) (Fig. 5).

DISCUSSION

The most important findings in this case series of 71 patients treated with a kinematically aligned, cruciate-retaining TKA were that the range of I-E malrotation of the tibial component was 4 times greater than the range of I-E malrotation of the femoral component, and that the range of I-E malrotation of the femoral component from -3° internal to 2° external and the range of I-E malrotation of the tibial component from -11° internal to 12° external were not associated with compromised function as measured by the OKS and WOMAC score.

Six limitations should be discussed as they could affect the generalization of the findings. First, the range of I-E malrotation of the femoral and tibial components is specific for both kinematically aligned TKA performed with generic instruments and the specific design of the tibial liner used in the present study that had a fairly flat articular surface that might accommodate tibial malrotation better than more constrained designs. Accordingly, these results might not apply to mechanically aligned TKA and tibial liners with a more constrained tibial articular surface. Second, the present study used an MR imaging plane that was rotationally aligned parallel to the F-E plane of the extended knee.¹⁷ The use of an MR imaging plane not rotationally aligned parallel to the F-E plane of the extended knee might yield different results from the present study. Third, although the New Zealand Joint Registry has shown that a high self-reported OKS at 6 months prognosticates a low revision rate at 2 years and high function at 5 years, the present study's functional analysis at 6 months is only predictive and does not determine long-term patient function and survival of the implant.¹⁶ However, the reported mid-term outcomes of the kinematic alignment TKA surgical technique at a mean of 6.3 years

(range, 5.8–7.2 years) had a survivorship of 97.5% and an average OKS of 43, which is comparable with the score of 42 in the present study.²¹ Fourth, the design features of the femoral component and tibial insert may affect the results. Fifth, the unique method described in the present study to compute I-E rotation of the femoral and tibial components from the F-E plane of the extended knee with use of MRI and CT images requires additional clinical evaluation and validation. Finally, dysplasia of a femoral condyle, in particular the lateral femoral condyle in the valgus osteoarthritic knee, could adversely affect the accuracy in setting the I-E rotation of the A-P axis of the femoral component when a 0° rotation posterior referencing guide is used. However, an analysis of 155 varus and 44 valgus deformities with end-stage osteoarthritis showed no evidence of dysplasia as the asymmetry between the radii of the medial and lateral femoral condyles was ≤ 0.2 mm.¹⁷ In the present study, the -3° internal to 2° external range of the I-E malrotation of the 59 varus and 22 valgus deformities confirms that dysplasia, if present, had a negligible clinical effect on setting the I-E rotation of the A-P axis of the femoral component parallel to the F-E plane of the extended knee.

The present study strived to align the I-E rotation of the femoral component parallel to the F-E plane of the extended knee, which is a less variable and a different alignment target than the 3 femoral reference lines used in mechanical alignment. Eleven arthroplasty surgeons each working with 10 cadaveric specimens reported that identifying the mechanical alignment femoral reference lines resulted in high variability as shown by the range of -11° internal to 16° external rotation for the transepicondylar axis, -12° internal to 15° external rotation for the A-P axis of the trochlear groove, and -10° internal to 12° external rotation for the line 3° externally rotated from the posterior condylar line.⁴ These mechanical alignment femoral reference lines are neither parallel nor perpendicular to the F-E plane of the extended knee, and when used may cause a ≥ 2 mm instability in a compartment between 0° and 90° of flexion that is uncorrectable by a collateral ligament release in 42% to 80% of knees.^{7,22,23} In contrast, the -3° internal to 2° external range of malrotation of the femoral component for a single arthroplasty surgeon in the present study was 4 to 5 times narrower. Because the limits of agreement of -1.9° to 2.2° , defined as the mean ± 2 SDs, are small enough to be clinically unimportant in terms of function, because the use of a posterior referencing guide is straightforward, and because the use of caliper is a simple check that the

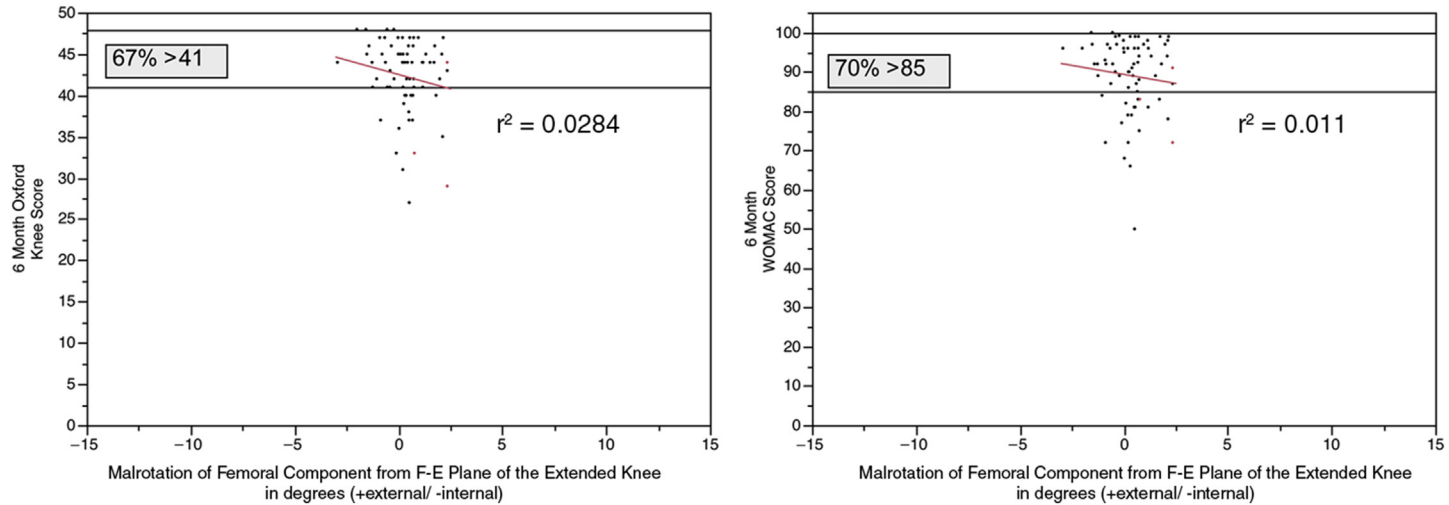


Fig. 4. Scatterplots show the weak association of the malrotation of the femoral component, which ranges from -3° internal to 2° external from the F-E plane of the extended knee, and the OKS ($r^2 = 0.0284$) and the WOMAC score ($r^2 = 0.011$) at 6 months. Percentages indicate the proportion of patients with a function score greater than the indicated value.

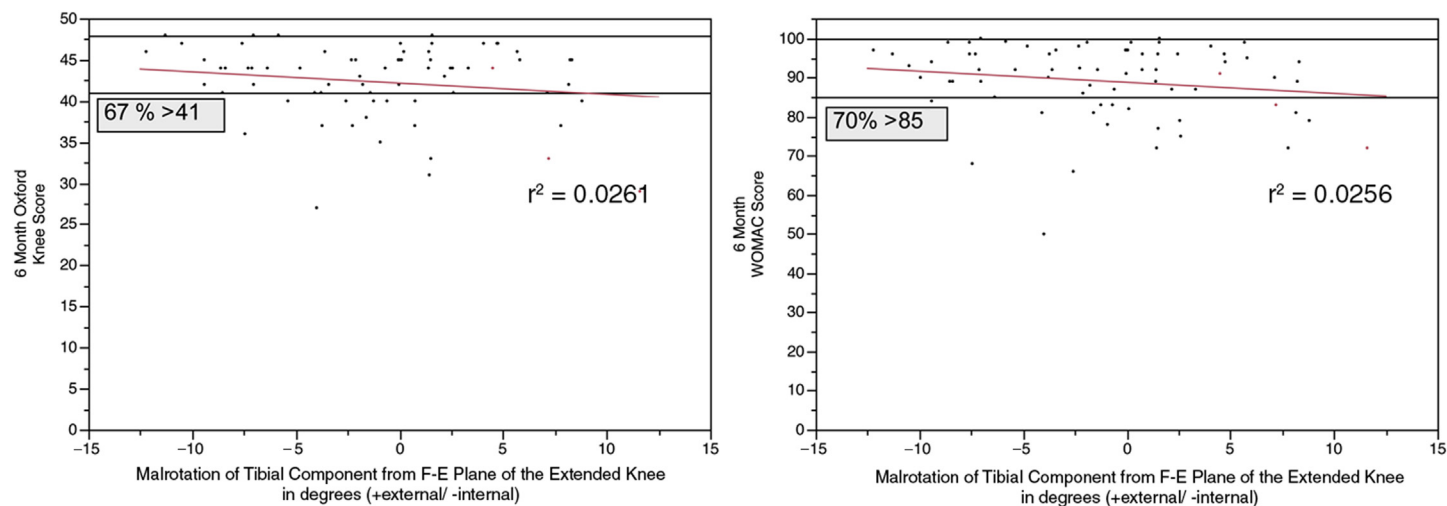


Fig. 5. Scatterplots show the weak association of the malrotation of the tibial component, which ranges from -11° internal to 12° external from the F-E plane of the extended knee, and the OKS ($r^2 = 0.0265$) and the WOMAC score ($r^2 = 0.0256$) at 6 months. Percentages indicate the proportion of patients with a function score greater than the indicated value.

intraoperative thickness of each posterior resection is correct, the ranges of agreement might not inflate to a clinically important level when this alignment method is used by other surgeons.

The present study strived to align the I-E rotation of the A-P axis of the tibial component parallel to the F-E plane of the extended knee with use of the long axis of the boundary of the articular surface of the lateral tibial condyle, which is a less variable and different target than the tibial reference lines commonly used in mechanical alignment. Eleven arthroplasty surgeons each working with 10 cadaveric specimens reported that identifying the mechanical alignment tibial reference lines resulted in high variability as shown by the range from -43° internal to 42° external rotation for the line connecting the center of the posterior cruciate ligament fossa to the medial border of the tibial tubercle, range from -40° internal to 46° external rotation for the line connecting the center of the posterior cruciate ligament fossa to the medial one-third of the tibial tubercle, and range from -20° internal to 32° external rotation for the line connecting the center of the posterior cruciate ligament fossa to the most anterior point of the tibial tubercle.³ The mechanical alignment tibial reference lines that reference the tibial tubercle are not useful landmarks when the goal is to set the I-E rotation of the A-P axis of the tibial component parallel to F-E plane of the extended knee because there is 15 mm of mediolateral variability of the location of the tibial tubercle on the tibia.¹⁸ In contrast, the method used in the present study to set I-E rotation of the tibial component, which yielded a -11° internal to 12° external range, was 2 to 3 times narrower. Although the limits of agreement of -7.4° to 10.4° are small enough to be clinically unimportant in terms of function, the use the long axis of the boundary of the articular surface of the lateral tibial condyle to set the I-E rotation of the tibial component requires intraoperative judgment and the ranges of agreement might inflate to a clinically important level when this alignment method is used by other surgeons.

In summary, even though the range of I-E malrotation of the tibial component can be 4 times greater than the range of I-E malrotation of the femoral component, this degree of I-E malrotation does not compromise function in kinematically aligned TKA with use of a fairly flat tibial articular surface. Hence, surgeons analyzing CT scans of kinematically aligned TKA should understand that I-E malrotation of the femoral and tibial components that are bounded by the ranges reported in the present study are compatible with a well-functioning TKA.

REFERENCES

1. Barrack RL, Schrader T, Bertot AJ, et al. Component rotation and anterior knee pain after total knee arthroplasty. *Clin Orthop Relat Res* 2001;(392):46–55.
2. Windsor RE, Scuderi GR, Moran MC, et al. Mechanisms of failure of the femoral and tibial components in total knee arthroplasty. *Clin Orthop Relat Res* 1989;(248):15–9 [discussion: 19–20].
3. Siston RA, Goodman SB, Patel JJ, et al. The high variability of tibial rotational alignment in total knee arthroplasty. *Clin Orthop Relat Res* 2006;452:65–9.
4. Siston RA, Patel JJ, Goodman SB, et al. The variability of femoral rotational alignment in total knee arthroplasty. *J Bone Joint Surg Am* 2005;87(10):2276–80.
5. Dossett HG, Estrada NA, Swartz GJ, et al. A randomised controlled trial of kinematically and mechanically aligned total knee replacements: two-year clinical results. *Bone Joint J* 2014;96-B(7):907–13.
6. Nam D, Nunley RM, Barrack RL. Patient dissatisfaction following total knee replacement: a growing concern? *Bone Joint J* 2014;96-B(11 Suppl A):96–100.
7. Eckhoff DG, Bach JM, Spitzer VM, et al. Three-dimensional mechanics, kinematics, and morphology of the knee viewed in virtual reality. *J Bone Joint Surg Am* 2005;87(Suppl 2):71–80.
8. Hollister AM, Jatana S, Singh AK, et al. The axes of rotation of the knee. *Clin Orthop Relat Res* 1993;(290):259–68.
9. Iwaki H, Pinskerova V, Freeman MA. Tibiofemoral movement 1: the shapes and relative movements of the femur and tibia in the unloaded cadaver knee. *J Bone Joint Surg Br* 2000;82(8):1189–95.
10. Pinskerova V, Iwaki H, Freeman MA. The shapes and relative movements of the femur and tibia at the knee. *Orthopade* 2000;29(Suppl 1):S3–5.
11. Weber WE, Weber EFM. *Mechanik der menschlichen Gehwerkzeuge*. Göttingen (Germany): Verlag der Dietrichschen Buchhandlung; 1836.
12. Coughlin KM, Incavo SJ, Churchill DL, et al. Tibial axis and patellar position relative to the femoral epicondylar axis during squatting. *J Arthroplasty* 2003;18(8):1048–55.
13. Iranpour F, Merican AM, Dandachli W, et al. The geometry of the trochlear groove. *Clin Orthop Relat Res* 2010;468(3):782–8.
14. Howell SM, Papadopoulos S, Kuznik KT, et al. Accurate alignment and high function after kinematically aligned TKA performed with generic instruments. *Knee Surg Sports Traumatol Arthrosc* 2013;21(10):2271–80.
15. Nedopil AJ, Howell SM, Rudert M, et al. How frequent is rotational mismatch within 0 ± 10 in kinematically aligned total knee arthroplasty? *Orthopedics* 2013;36(12):e1515–20.

16. Listed NA. The New Zealand joint registry fourteen year report. Available at: <http://www.nzoa.org.nz/nz-joint-registry>. Accessed December 20, 2014.
17. Howell SM, Howell SJ, Hull ML. Assessment of the radii of the medial and lateral femoral condyles in varus and valgus knees with osteoarthritis. *J Bone Joint Surg Am* 2010;92(1):98–104.
18. Howell SM, Chen J, Hull ML. Variability of the location of the tibial tubercle affects the rotational alignment of the tibial component in kinematically aligned total knee arthroplasty. *Knee Surg Sports Traumatol Arthrosc* 2013;21(10):2288–95.
19. Nam D, Lin KM, Howell SM, et al. Femoral bone and cartilage wear is predictable at 0 degrees and 90 degrees in the osteoarthritic knee treated with total knee arthroplasty. *Knee Surg Sports Traumatol Arthrosc* 2014;22(12):2975–81.
20. Bedard M, Vince KG, Redfern J, et al. Internal rotation of the tibial component is frequent in stiff total knee arthroplasty. *Clin Orthop Relat Res* 2011;469(8):2346–55.
21. Howell SM, Papadopoulos S, Kuznick K, et al. Does varus alignment adversely affect implant survival and function six-years after kinematically aligned total knee arthroplasty? *Int Orthop* 2015. [Epub ahead of print].
22. Eckhoff D, Hogan C, DiMatteo L, et al. Difference between the epicondylar and cylindrical axis of the knee. *Clin Orthop Relat Res* 2007;461:238–44.
23. Gu Y, Roth JD, Howell SM, et al. How frequently do four methods for mechanically aligning a total knee arthroplasty cause collateral ligament imbalance and change alignment from normal in white patients? *J Bone Joint Surg Am* 2014;96(12):e101.